

Are the Rule 20 Treatment Guidelines Still Valid? (Or, How We Become Slaves to the Machine)

Chris Martin, MD, MSc
Professor
Schools of Public Health and Medicine

West Virginia University
cmartin@hsc.wvu.edu

Background

- “Medical Management of Claims, Guidelines for Impairment Evaluations, Evidence, and Ratings, and Ranges of Permanent Partial Disability Awards”
- Focus on:
 - Medical management: Why do we need treatment guidelines?
 - Causality: What is pre-existing versus work-related?
 - Impairment ratings

Real Case

- Seen for CME on 3/10/2026
- 50-year-old female radiologic technologist, right hand dominant, with date of injury of 3/23/2021
- First medical 17 days after date of injury (“I’m stubborn”):

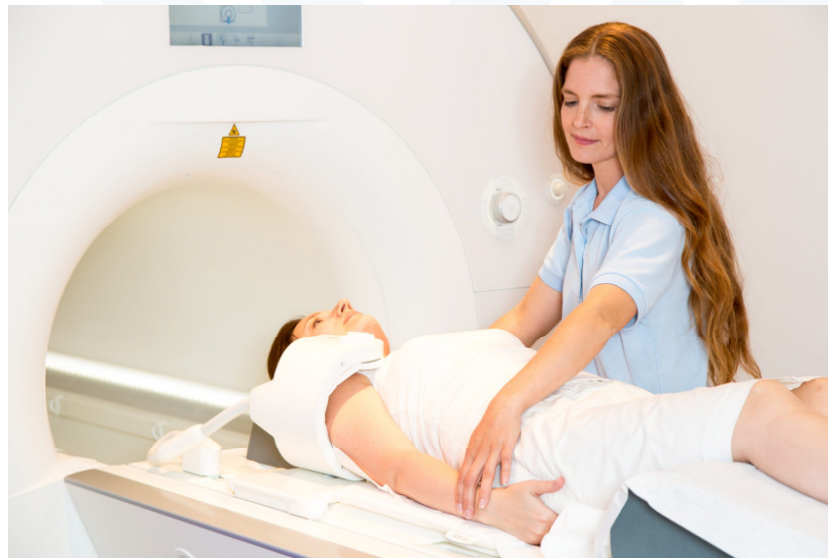“pt c/o left shoulder pain pt states she was pulling a pt up from a bed to xray and she felt a pull in her left shoulder 2 weeks ago c/o pain and decreased rom, shoulder not getting any better.

Left shoulder tender decreased rom

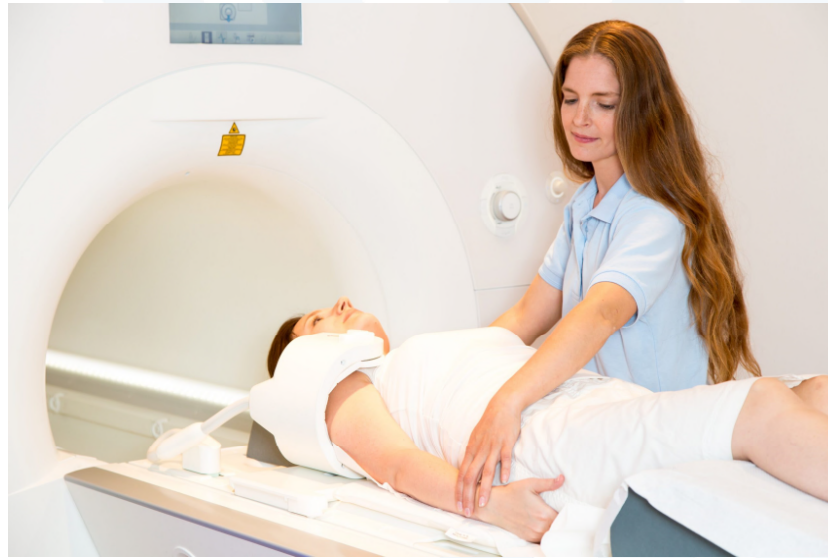Positive apley scratch test pt not able to reach left hand behind head to try and touch her opposite shoulder.”

- X-ray and MRI ordered left shoulder

Thank goodness we have this!



We love high tech



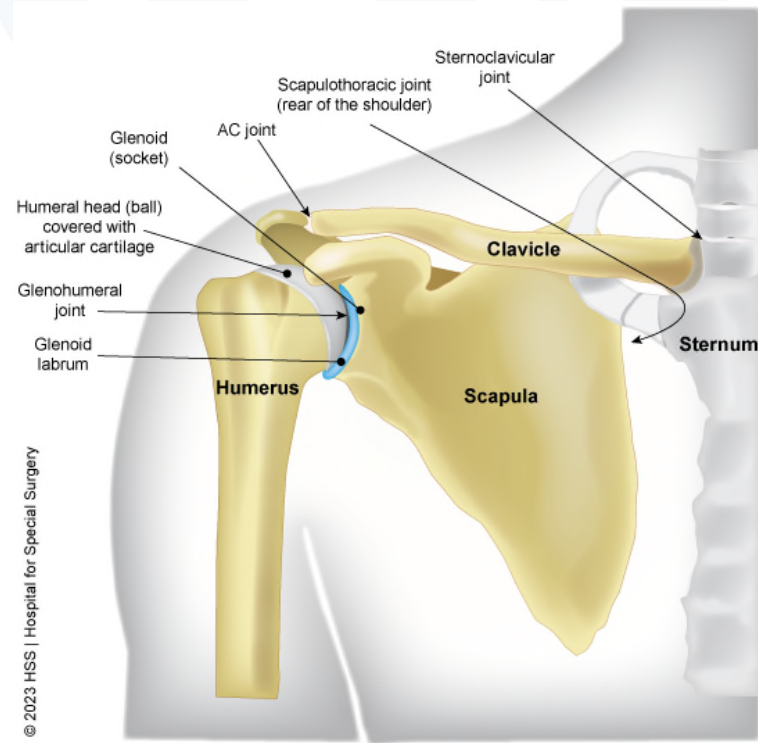
But advanced technology doesn't automatically mean the result is correct or the treatment is effective.

Case

- MRI

- April 24, 2021, 2 weeks after first visit
- “Large labral tear. This extends superiorly and anteriorly and posteriorly.”

Labral tears



Case

- Sees orthopedic surgeon June 2, 2021, removed from work
 - Had continued to work without restrictions for 9 weeks after injury
- Recommends surgery to repair labral tear, followed by physical therapy

Case

- After repair of labral tear
 - Patient: worse, persistent pain, reduced range of motion, stiffness
 - Diagnosed as having adhesive capsulitis (frozen shoulder)
 - Physical therapy (PT) to improve range of motion

Case

- No improvement with PT
- Second surgery:
 - Lysis of adhesion from prior surgery, manipulation under anesthesia, debridement, removal 2 loose pieces of cartilage
 - More PT
 - Patient: no better
- Orthopedic surgeon: “Unfortunately, she has had a very difficult and protracted recovery. She has had a really bad case of adhesive capsulitis....we are just swimming upstream.”

Case

- Patient sees new orthopedic surgeon out-of-state
- Third surgery:
 - Debridement; manipulation under anesthesia, capsular release; and subacromial decompression
 - Patient: no better

Case

- >150 sessions PT
- 8 injections: “They barely take the pain away”
- Never returned to work, states progressively worse
- Orthopedic surgeon at last visit, January 2026
 - Ordered MRI (4th of left shoulder) which revealed inflammation, fraying of bursa
 - Performed 8th injection
 - Discusses additional surgical procedure with patient to address frozen shoulder, repeating what was done in two previous surgeries

With the benefit of hindsight...

- Patient: She would have been better off if she never sought medical care
 - “I have lost trust.”
- Doctor: We failed a patient
- Workers’ compensation insurer: Paid for three surgeries, 8 injections, >150 sessions of PT, 5 MRIs of the shoulder, X-rays, maximum period of TTD, and a 12% PPD award
- Society: A woman’s life was ruined
 - Iatrogenic disability: lost an excellent rad tech at age 50
 - Hospital has a current job vacancy for a rad tech

The MRI is a wonderful slave and a terrible master

Injured worker

Seeks medical attention:

- Minimal history and exam
- Imaging ordered immediately

Imaging

Investigation:

- Abnormality found
- Assumed to be caused by the injury
- Assumed to be the source of the symptoms
- The finding becomes the diagnosis

Specialist

Based on result:

- Removal from work
- Surgery

How can we do better?

Rule 20 for the shoulder, section 40.2:

“The appropriate diagnostic criteria are as follows:

a. History and physical.

1. Mechanism of injury”

What we are taught in medical school

1. Take a good history

- “Listen to your patient; he is telling you the diagnosis.”
- Sir William Osler
- A correct diagnosis is made by history in ~80% of cases
 - True for ChatGPT too!*

2. Perform a physical examination

3. Develop a differential diagnosis

4. Order investigations to confirm that diagnosis

How can we do better?

Rule 20 for shoulder, section 40.3:

“2. Special imaging - requires pre-authorization and specialty referral.

- A. CT scan;
- B. MRI;”

Key Point

- No test is perfect, there are always false positive and negative results
- We can minimize these errors by carefully selecting who to test based on clinical assessment
 - Maximize the pre-test probability of disease



Sutton's Law

- Q: "Why do you rob banks?"
- A: "That's where the money is!"

Key Point

- Consider a positive cardiac stress test in a patient who reports chest pain:
 1. ...only with exertion in a 65-year-old man with a 45-pack-year history of smoking, poorly controlled hypertension, hyperlipidemia, obesity, diabetes, and a strong family history of heart disease
 2. ...at rest in a 21-year-old woman who has never smoked, is otherwise healthy and is on the WVU swim team
- But, in both cases, all we know is the test is positive
- Only perform the test in the right patient

Labral tears - mechanism of acute injury

- Fall on outstretched arm (50% of cases in classic case series)
- Or
- Traction
- Her history: Pulling a quadriplegic patient she estimates weighed 250 lbs on a table toward her using a sheet with both arms.
- Does her reported mechanism of injury fit?

Labral tears - history

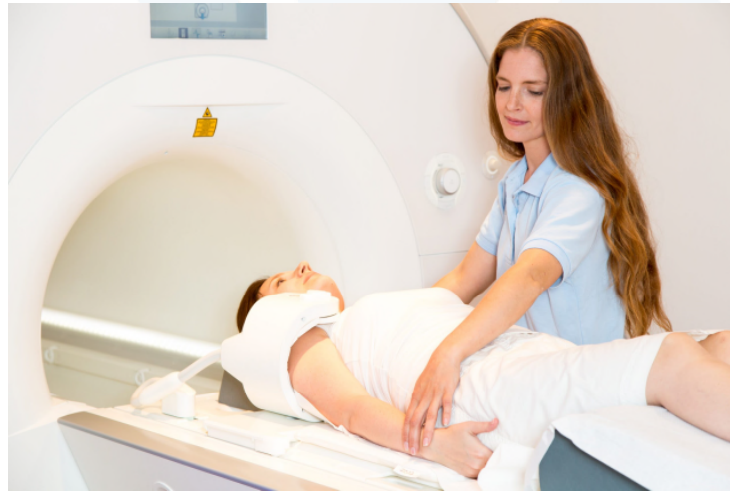- What are the symptoms?
 - “Deep” pain
 - Feeling of instability
 - Mechanical symptoms: popping, clicking
- Her symptoms: in both shoulders:
 - Pain L > R
 - Instability and mechanical symptoms R > L

Labral tears – physical examination

“Because this cartilage is deep in the shoulder, it is very difficult to make the diagnosis of a torn labrum upon physical examination. There are several tests that the physician can perform that may indicate a torn labrum, but these tests are not always accurate.... Some physicians feel very confident that they can make the diagnosis of a labral tear upon physical examination, but this is controversial. There are not many scientific studies that show that physical examination is reliable for making the diagnosis of a labral tear. As a result of this uncertainty, other studies can be done to confirm the diagnosis if it is suspected.”



Thank goodness we have this!



But.....

Finding	Prevalence in Asymptomatic Population	Source
Superior labral tears in shoulder on MRI	55% and 72% Only “moderate” agreement between radiologists	Schwartzberg R, Reuss BL, Burkhart BG, Butterfield M, Wu JY, McLean KW. High Prevalence of Superior Labral Tears Diagnosed by MRI in Middle-Aged Patients With Asymptomatic Shoulders. Orthop J Sports Med. 2016 Jan 5;4(1):2325967115623212.

Finding	Prevalence in Asymptomatic Population	Source
Superior labral tears in shoulder on MRI	55% and 72% Only “moderate” agreement between radiologists	Schwartzberg R, Reuss BL, Burkhart BG, Butterfield M, Wu JY, McLean KW. High Prevalence of Superior Labral Tears Diagnosed by MRI in Middle-Aged Patients With Asymptomatic Shoulders. Orthop J Sports Med. 2016 Jan 5;4(1):2325967115623212.

And it gets worse....

Finding	Prevalence in Asymptomatic Population	Source
Superior labral tears in shoulder on MRI	55% and 72% Only “moderate” agreement between radiologists	Schwartzberg R, Reuss BL, Burkhart BG, Butterfield M, Wu JY, McLean KW. High Prevalence of Superior Labral Tears Diagnosed by MRI in Middle-Aged Patients With Asymptomatic Shoulders. <i>Orthop J Sports Med.</i> 2016 Jan 5;4(1):2325967115623212.
EMG/NCS report showing carpal tunnel syndrome	18.4%	Atroshi I, Gummesson C, Johnsson R, Ornstein E, Ranstam J, Rosén I. Prevalence of carpal tunnel syndrome in a general population. <i>JAMA.</i> 1999 Jul 14;282(2):153-8.
Full thickness rotator cuff tear in shoulder on MRI	0 to 100%!	Sanders S, Ibounig T, Haas R, Jones M, Rämö L, Docking S, Järvinen T, Taimela S, Hoffmann T, Buchbinder R. Rotator Cuff Imaging Abnormalities in Asymptomatic Shoulders: A Systematic Review. <i>J Orthop Sports Phys Ther.</i> 2025 Dec;55(12):1-16.
Abnormal MRI of the lumbosacral spine	64% overall 52% disc bulge 19% disc herniation 14% annular defects	Jensen MC, Brant-Zawadzki MN, Obuchowski N, Modic MT, Malkasian D, Ross JS. Magnetic resonance imaging of the lumbar spine in people without back pain. <i>N Engl J Med.</i> 1994 Jul 14;331(2):69-73.
Abnormal MRI of the knee	97% overall 30% meniscal tears	Horga LM, Hirschmann AC, Henckel J, Fotiadou A, Di Laura A, Torlasco C, D'Silva A, Sharma S, Moon JC, Hart AJ. Prevalence of abnormal findings in 230 knees of asymptomatic adults using 3.0 T MRI. <i>Skeletal Radiol.</i> 2020 Jul;49(7):1099-1107.

What I tell my patients: The inside of our bodies are like the outside



In many (or most?) cases:

- Such imaging findings were pre-existing
- They were NOT caused by an injury
- They did NOT cause symptoms before the injury
- They are NOT causing symptoms after the injury
- They are incidental findings
- Surgically correcting incidental imaging findings does not help patients!

Implications for impairment ratings

- Formulating an impairment based solely on an imaging finding without a supportive clinical correlation is not justified
- So is apportionment of an impairment based solely on imaging findings



Implications for impairment ratings: Rule 20

TABLE §85-20-C. PPD Ranges for Lumbar Spine Impairments

Criteria for Rating Impairment Due to Lumbar Spine Injury				
Lumbar Category I 0% Impairment of the Whole Person	Lumbar Category II 5%-8% Impairment of the Whole Person	Lumbar Category III 10%-13% Impairment of the Whole Person	Lumbar Category IV 20%-23% Impairment of the Whole Person	Lumbar Category V 25%-28% Impairment of the Whole Person
No significant clinical findings, no observed muscle guarding or spasm, no documentable neurologic impairment, no documented alteration in structural integrity and no other indication of impairment related to injury or illness, no fractures	Clinical history and examination findings are compatible with a specific injury; findings may include significant muscle guarding or spasm observed at the time of the examination, asymmetric loss of range of motion, or non-verifiable radicular complaints , defined as complaints of radicular pain without objective findings; no alteration of the structural integrity and no significant radiculopathy or individual had a clinically significant radiculopathy and has an imaging study that demonstrates a herniated disk at the level and on the side that would be expected based on the previous radiculopathy, but no longer has the radiculopathy following conservative treatment or fractures: (1) less than 25% compression of one vertebral body; (2) posterior element fracture without dislocation (not developmental spondylolysis) that has healed without alteration of motion segment integrity; (3) a spinous or transverse process fracture with displacement without a vertebral body fracture, which does not disrupt the spinal canal	Significant signs of radiculopathy, such as dermatomal pain and/or in a dermatomal distribution, sensory loss, loss of relevant reflex(es), loss of muscle strength or measured unilateral atrophy above or below the knee compared to measurements on the contralateral side at the same location; impairment may be verified by electrodiagnostic findings or history of a herniated disk at the level and on the side that would be expected from objective clinical findings , associated with radiculopathy, or individuals who had surgery for radiculopathy but are now asymptomatic or fractures: (1) 25% to 50% compression of one vertebral body; (2) posterior element fracture with displacement disrupting the spinal canal; in both cases, the fracture has healed without alteration of structural integrity	Loss of motion segment integrity defined from flexion and extension radiographs as at least 4.5 mm of translation of one vertebra on another or angular motion greater than 15° at L1-2, L2-3 and L3-4, greater than 20° at L4-5, and greater than 25° at L5-S1 (Figure 15-3); may have complete or near complete loss of motion of a motion segment due to developmental fusion, or successful or unsuccessful attempt at surgical arthrodesis or fractures: (1) greater than 50% compression of one vertebral body without residual neurologic compromise	Meets the criteria of DRE lumbosacral categories III and IV; that is, both radiculopathy and alteration of motion segment integrity are present; significant lower extremity impairment is present as indicated by atrophy or loss of reflex(es), pain and/or sensory changes within an anatomic distribution (Dermatomal), or electromyographic findings as stated in lumbosacral category III and alteration of spine motion segment integrity as defined in lumbosacral category IV or fractures: (1) greater than 50% compression of one vertebral body with unilateral neurologic compromise

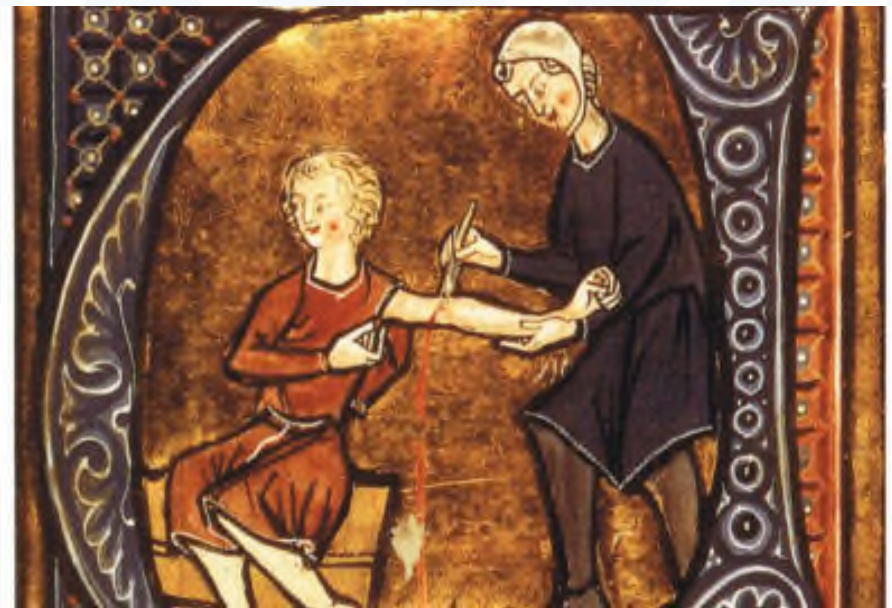Category II: If “non-verifiable radicular complaints”, name the specific nerve root!
 Category III: For radiculopathy, imaging must correlate with clinical findings.

From a medical perspective, why does this happen?

- The average visit with a primary care provider is about 15 minutes with about 5 minutes of direct conversation
 - This is getting better with adoption of AI
- Defensive medicine
- Our system is fee-for-service
 - The perverse incentives of healthcare
 - Most physicians have productivity targets
 - If you pay for it, it will be done!
 - Once investigations exhausted, start all over
 - The annual MRI!

From medical perspective, why does this happen?

- Physicians:
 - Genuinely want to help patients
 - Fool ourselves
 - Are not good at giving up



From a system perspective, we need more of this:

Research

JAMA Internal Medicine | [Original Investigation](#) | [LESS IS MORE](#)

Incidental Rotator Cuff Abnormalities on Magnetic Resonance Imaging

Thomas Ibounig, MD; Teppo L. N. Järvinen, MD, PhD; Saara Raatikainen, MSc; Tommi Härkänen, PhD; Niko Sillanpää, MD, PhD; Frank Bensch, MD, PhD; Ville Haapamäki, MD, PhD; Pirjo Toivonen, PT; Robert Björkenheim, MD, PhD; Anssi Ryösä, MD, PhD; Kari Kanto, MD, PhD; Vesa Lepola, MD, PhD; Antti Joukainen, MD, PhD; Mika Paavola, MD, PhD; Seppo Koskinen, MD, PhD; Lasse Rämö, MD, PhD; Rachelle Buchbinder, MD, PhD; Simo Taimela, MD, PhD

“Population-based cross-sectional study in a nationally representative random sample of adults aged 41 to 76 years who underwent standardized clinical assessment and bilateral 3-Tesla magnetic resonance imaging (MRI) of the shoulders conducted from February 2023 to April 2024 in Finland.”

Table 3. Prevalence of Rotator Cuff Abnormalities on MRI Per Shoulder According to the Absence or Presence of Current Shoulder Symptoms in 1204 Shoulders and Differences in Prevalence Adjusted by Clinically Relevant Confounders^a

Rotator cuff finding on MRI	Asymptomatic (n = 1076)		Symptomatic (n = 128)		Difference in prevalence, % (95% CI) ^c		
	Patients, No.	Prevalence, % (95% CI) ^b	Patients, No.	Prevalence, % (95% CI) ^b	Model 1: population prevalence ^b	Model 2: plus other imaging abnormalities ^d	Model 3: plus clinical rotator cuff tests ^e
Normal	37	3.9 (2.4 to 5.7)	2	2.1 (0.0 to 6.2)	-1.8 (-4.7 to 2.9)	-1.8 (-4.8 to 2.9)	-2.5 (-5.2 to 2.0)
Tendinopathy	427	38.9 (35.2 to 42.2)	34	30.4 (22.7 to 39.4)	-8.4 (-17.3 to 1.1)	-7.8 (-16.9 to 2.1)	-3.3 (-12.9 to 7.7)
Partial-thickness tear	537	50.6 (46.9 to 54.3)	71	52.8 (42.2 to 61.8)	2.1 (-8.8 to 12.8)	2.9 (-7.5 to 13.2)	5.0 (-6.0 to 16.0)
Full-thickness tear	75	6.5 (4.9 to 8.3)	21	14.6 (8.8 to 20.4)	8.1 (1.8 to 15.1)	6.7 (1.4 to 12.2)	0.8 (-3.4 to 6.0)

Abbreviation: MRI, magnetic resonance imaging.

^a MRI findings for each shoulder were classified according to the most severe abnormality detected in any tendon. Intermittent or continuous shoulder symptoms were those that lasted at least 1 day during the past week.

^b Adjusted for age, sex, education, and region.

^c The difference in prevalence is calculated as the prevalence in symptomatic

minus prevalence in asymptomatic participants.

^d Adjusted for age, sex, education, region, and coexisting MRI-detected shoulder abnormalities.

^e Adjusted for age, sex, education, region, coexisting MRI-detected shoulder abnormalities, and positive clinical rotator cuff tests.

“RC abnormalities were nearly universal after age 40 years and showed poor concordance with shoulder symptoms.”

“a positive MRI result does not confirm causality unless features such as a clear traumatic event, acute strength loss, or persistent functional deficit increase the pretest probability. This approach minimizes anchoring on incidental findings and supports proportionate, patient-centered care.”

More on patient

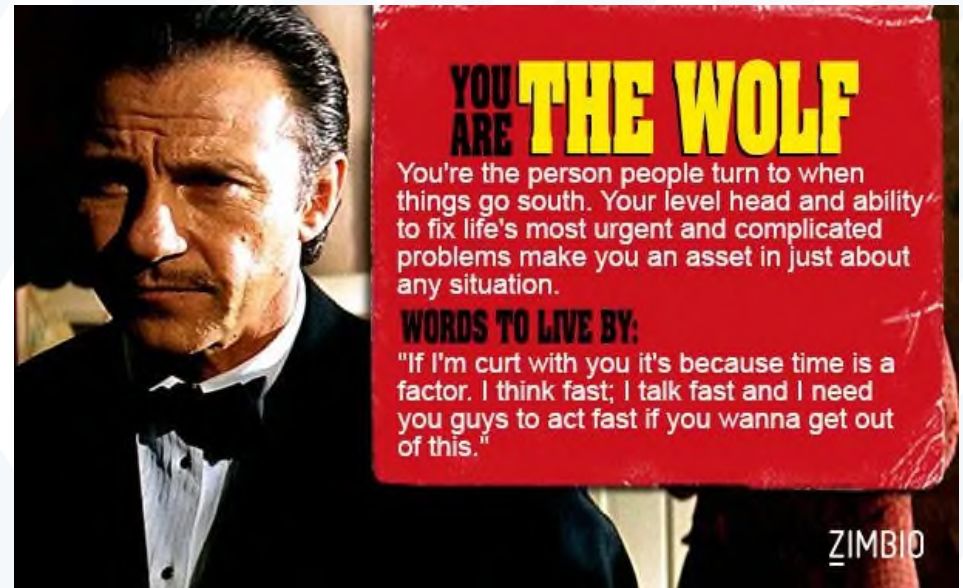
- Meticulously groomed
- Has a spiral notebook with all details of history
- Interrupts to correct me frequently
- Blunt affect
- When asked about future plans for employment, continues to express desire to have shoulder “fixed” so she can return to work as rad tech
- Becomes tearful when told she would not benefit from any further medical or surgical care
- What impact did learning she have a large labral tear have on her?

From employer's perspective

- Why remove a worker 9 weeks after an acute injury?
- Removal from work is a powerful intervention
 - The likelihood of returning to work declines exponentially with time off work
- Do you contact injured employees while they are off?
- Do you offer modified duties?
- Do you expect employee's "to be 100%" before returning to work?
- Return to work is therapeutic

From insurer's perspective, consider:

- EARLY medical input
- Reassurance and conservative care first, as per Rule 20
- Judicious use of advanced imaging and only in correct clinical context



Are the Rule 20 Treatment Guidelines Still Valid?

YES!

Questions?